



PATIENT

Mercy Depland

PRESENTING CLINICAL SIGNS

History: Coughing - not resolving on antibiotics. Treated with Lasix and condition has improved. CXR: Severe lung field congestion, possible diffuse neoplasia.

SPECIES

Feline

RADIOGRAPHIC FINDINGS *NOTE: Images submitted for supplemental cardiac information only. Normal cardiac silhouette. No obvious evidence of CHF.

BREED

DLH

ECHOCARDIOGRAM FINDINGS

2D, m-mode, color flow and doppler imaging is available. The left ventricular wall is normal in dimension. There is a mildly hyperechoic endocardium consistent with mild fibrosis. The endocardium also appears mildly remodeled. The papillary muscles are normal in size and hyperechoic. The left atrium is normal in size. The right atrium is normal in size. The right ventricle appears normal. The mitral valve is normal in structure and mobility. No obvious valve regurgitation. Blood flow through both the LVOT and RVOT is normal in velocity. No pleural or pericardial effusion seen. No obvious cardiac tumors.

AGE

14 years

CARDIAC CHART

WEIGHT

10lbs

FELINE CARDIAC PARAMETERS	BODY WEIGHT (kg)	HR (BPM)	IVSd (cm) (Moise, Pipers)	LVIDd (cm) (Moise, Pipers)	LWVd (cm) (Moise, Pipers)	FS (%)	EF (%)
NORMAL PARAMETER	-----	150-240	0.35-0.55	<2 (mean 1.5)	3.5-0.55	35-67	80-100
PATIENT	4.5	220	0.43	1.2	0.43	60	94
FELINE CARDIAC PARAMETERS	LA/AO (Boon)	LA/AO HEART BASE (Swe) (Abbott)	LA 2D short axis Base view (cm) (Abbott)		LVOT VEL (m/s)	RVOT VEL (m/s)	E max (m/s)
NORMAL	<1.5	<1.3	<1.2		<1.6	<1.3	<0.9
PATIENT	NM	1.3	1.2		1.1	0.8	NM

INTERPRETED BY

Maggie Machen Lamy, DVM, DACVIM (Cardiology)

*Note: All measurements based upon multi-modal images and methods. An average value is reported.

Adapted from June Boon, Veterinary Echocardiography, 1998

Abbott J & MacLean H JVIM 2006;20: 111-119, Moise et al. Am J Vet Res 47:1476, 1986. Pipers et al. Am J Vet Res 40:882, 1979.

IMAGING PERFORMED BY

Sands Hill Mobile Veterinary Ultrasound

HOSPITAL NAME

Surf City Animal Hospital

INTERPRETATION OF THE FINDINGS & FURTHER RECOMMENDATIONS

Overtly normal cardiac structure and function. The LV wall thickness is normal, and there is no evidence of elevated left atrial pressure or underlying pathology at this time. There is mild remodeling and fibrosis of the left ventricular wall, which is considered likely a normal age-related finding. Given these findings, no medications are indicated.

REFERRING VET

Dr. Wick

These findings would suggest respiratory changes are noncardiac in origin. From a cardiac standpoint, there is no indication for continued Lasix therapy. Consider respiratory/pulmonary evaluation, including a Radiologist review of the film, focus thoracic ultrasound, thoracic CT scan, etc.

INVOICE

29036

DATE

2/16/23

Anesthetic risk is considered mild. With remodeling and diastolic stiffening, there is an elevated risk for fluid overload in this patient and judicious IV fluid use is recommended. Heart rate stimulating drugs such as atropine, glycopyrrolate or ketamine should be avoided unless



PATIENT

Mercy Depland

medically necessary. Risk for complication with steroid use typically follows LA dilation, which in this case is low. That being said, any cat can experience unexpected signs of intolerance and monitoring of RR/RE is advised particularly in the initiation phase.

SPECIES

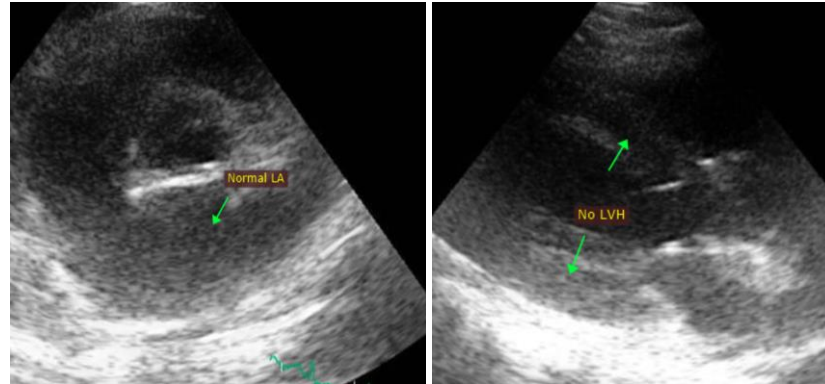
Feline

Recommend recheck echocardiogram in 1 year to assess for any progressive issues.

IMAGES

BREED

DLH



SEX

Female Spayed

AGE

14 years

WEIGHT

10lbs

The information and recommendations provided are based on the images presented by the referring veterinarian. No evaluation can be communicated regarding pathology that was not visible in the image/video clips provided.

INTERPRETED BY

Maggie Machen Lamy,
DVM, DACVIM
(Cardiology)

Thank you for this referral. This report was generated using transcription software, and minor dictation errors may be present. If the clinical or image interpretation does not parallel your findings or if I can be of any further assistance, please contact me.

Maggie Machen Lamy, DVM
Diplomate of the American College of Veterinary Internal Medicine (Cardiology)
info@sonopath.com

IMAGING PERFORMED BY

Sands Hill Mobile
Veterinary Ultrasound

HOSPITAL NAME

Surf City Animal
Hospital

REFERRING VET

Dr. Wick

INVOICE

29036

DATE

2/16/23